

ASSESSMENT OF GALL BLADDER DISEASES USING ULTRASONOGRAPHY

Dinesh Kumar Singh¹¹Associate Professor, Varun Arjun Medical College, Shahjahanpur, Uttar Pradesh, India.

Received : 05/03/2023
 Received in revised form : 13/04/2023
 Accepted : 26/04/2023

Keywords:
 Acute cholecystitis, Gall stones,
 ultrasonography.

Corresponding Author:
Dr. Dinesh Kumar Singh,
 Email: drdksingh999@gmail.com

DOI: 10.47009/jamp.2023.5.3.91

Source of Support: Nil,
 Conflict of Interest: None declared

Int J Acad Med Pharm
 2023; 5 (3); 424-427



Abstract

Background: To assess gall bladder diseases using ultrasonography. **Materials and Methods:** Eighty patients with gall bladder diseases of both genders underwent USG performed with a 3.5-5 MHz probe by scanning in subtotal position. Scan with the probe in longitudinal plane was performed after applying warm gel to the area after removing clothing away from abdomen with the patient in the supine position. The probe was orientated cephalic. Once the gallbladder was clearly identified, longitudinal and transverse views of the gallbladder was obtained. **Result:** Out of 80 patients, males were 50 (62.5%) and females were 30 (37.5%). Common clinical findings were nausea /vomiting in 52, upper abdominal pain 73, jaundice in 50, weight loss in 12, itching in 14 patients and upper abdominal mass in 8 patients. The difference was significant ($P < 0.05$). Common pathologies were polyps in 20, benign tumor in 14, acute cholecystitis in 13, chronic cholecystitis in 7 and gall stones in 25 patients. The difference was significant ($P < 0.05$). USG findings were slight contraction in 56%, wall thickening was seen in 82%, acute acalculouscholecystitis in 14% and pericholecystic edema in 23%. The difference was significant ($P < 0.05$). **Conclusion:** Common USG findings were slight contraction, wall thickening, acute acalculouscholecystitis and pericholecystic edema. Common GB diseases were polyps, benign tumor, acute cholecystitis, chronic cholecystitis and gall stones.

INTRODUCTION

Gallbladder diseases constitute a significant health problem in developed societies, affecting 10% to 15% of the adult population. Gallbladder diseases are commonly seen in middle aged female population and they are present mostly in the western world. The prevalence of this disease is 10% to 20% of the world population. The prevalence in India has been reported as 2 to 29% and seven times more common in the north India. 10% of the adult patients have asymptomatic gall stones. The prevalence varies with age, sex and ethnic group. The risk factors of cholesterol gallstone formation are ethnic background, age, female sex, family history and genetic factors.^[1] The modifiable risk factors include obesity, rapid weight loss and physical inactivity. Gallbladder disease is multi-factorial in origin including infections, genetic susceptibility and modifiable lifestyle factors. There is significant difference in rates of gallbladder disease by ethnicity/race and geography. The prevalence is highest among Hispanic populations of Central and South American and in individuals with Native American ancestry. In developed countries, gallbladder diseases occur due to formation of cholesterol gallstones and while most

of these gallstones are clinically silent, 20% of people harboring stones experience biliary symptoms. The incidence of gallbladder diseases is more common in India.^[2]

Emergency conditions involving the gallbladder and the bile ducts are common radiological challenging problems.^[3] Imaging provides valuable information for the following reasons to ensure the final diagnosis, as up to 20% of patients clinically classified as having acute cholecystitis have another disease that does not require surgery, to prevent the patient from complications in case of delayed diagnosis and to detect complications which may urge the surgical treatment.^[4] Ultrasonography has become the diagnostic test of choice for detecting gallstones and other diseases of the biliary system. Ultrasonography is the technique of choice in diagnosing gallbladder calculi. In the mid-1970s ultrasound was only accurate enough to use as an adjunct to oral cholecystography but refinements such as gray scale and real-time imaging mean that in experienced hands it has a sensitivity of 96% and a specificity of 93%.^[5] Sonography is also the test of choice in the initial evaluation of jaundiced patients. It is an excellent technique for distinguishing between obstructive and nonobstructive jaundice, although it is less accurate in demonstrating the

cause of the obstruction.^[6] We performed this study to assess ultrasonography in diagnosis of gall bladder diseases.

MATERIALS AND METHODS

After considering the utility of the study and obtaining approval from ethical review committee, we selected eighty patients with gall bladder diseases of both genders. Patients' consent was obtained before starting the study.

Data such as name, age, gender etc. was recorded. USG was performed with a 3.5-5 MHz probe by scanning in subtotal position. Scan with the probe in

longitudinal plane was performed after applying warm gel to the area after removing clothing away from abdomen with the patient in the supine position. The probe was orientated cephalic. Once the gallbladder was clearly identified, longitudinal and transverse views of the gallbladder was obtained. The results were compiled and subjected for statistical analysis using Mann Whitney U test. P value less than 0.05 was set significant.

RESULTS

Out of 80 patients, males were 50 (62.5%) and females were 30 (37.5%) [Table 1].

Table 1: Patients distribution

Total- 80		
Gender	Males	Females
Number (%)	50 (62.5%)	30 (37.5%)

Table 2: Clinical findings in patients

Clinical findings	Number	P value
Nausea /Vomiting	52	0.02
Upper abdominal pain	73	
Jaundice	50	
Weight loss	12	
Itching	14	
Upper abdominal mass	8	

Table 3: Gall bladder pathologies

Pathologies	Number	P value
Polyps	20	0.03
Benign tumor	15	
Acute Cholecystitis	13	
Chronic cholecystitis	7	
Gall stones	25	

Table 4: Assessment of ultrasonographic findings

Ultrasonographic findings	Percentage	P value
Slight contraction	56%	0.05
Wall thickening	82%	
Acute acalculouscholecystitis	14%	
Pericholecystic edema	23%	

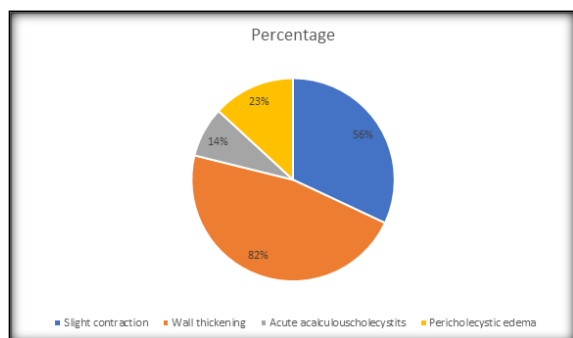


Figure 1: Assessment of ultrasonographic findings

Common clinical findings were nausea /vomiting in 52, upper abdominal pain 73, jaundice in 50, weight loss in 12, itching in 14 patients and upper abdominal mass in 8 patients. The difference was significant ($P < 0.05$) [Table 2].

Common pathologies were polyps in 20, benign tumor in 14, acute cholecystitis in 13, chronic

cholecystitis in 7 and gall stones in 25 patients. The difference was significant ($P < 0.05$) [Table 3].

USG findings were slight contraction in 56%, wall thickening was seen in 82%, acute acalculouscholecystitis in 14% and pericholecystic edema in 23%. The difference was significant ($P < 0.05$) [Table 4].

DISCUSSION

Gallbladder diseases are very common entities with diverse features of presentation at clinical, radiological and pathological settings with variable morbidity and mortality. It implies an altered hepatobiliary function. Majority of gallbladder diseases involves gallstones, which form about 95% of the all-gallbladder diseases and non-calculus disease form about 5%.^[7] Acute or chronic inflammations of gallbladder, commonly seen in association with calculus gallbladders.^[8] Benign

neoplasms are very rare, whereas malignant neoplasms are more common than benign neoplasms but uncommon compared to inflammatory conditions. Ultrasound is non-invasive and is not painful. Ultrasound is effective in diagnosis of cholelithiasis, pericholecystic fluid and a thickened wall of gallbladder.^[9] Ultrasound produces good images of the small ducts in the liver and the higher part of the major bile duct.^[10] A sonogram of a normal gallbladder shows the common bile duct anterior to the right portal vein and right hepatic artery.^[11] Connective tissue around the neck of the gallbladder and cystic duct areas can produce dense echoes with distal shadowing.^[12,13] We performed this study to assess ultrasonography in diagnosis of gall bladder diseases.

Our results showed that out of 80 patients, males were 50 (62.5%) and females were 30 (37.5%). Ghafoor et al,^[14] found that the mean age of the patients was 60 years with female preponderance. About 40% of the gall-bladder were contracted and reduced in size and 32.5% large and distended on USG examination, while 45% of the gall-bladder were contracted and reduced in size and 25% distended and large on CT examination. Approximately 40% had irregularly thickened wall and 21.2% diffusely thickened wall on USG and 30% of gallbladder wall were diffusely thickened and 45% irregularly thickened on CT scan. The present study showed hepatic parenchymal invasion to be 22.5% on USG and 42.5% on CT scan. The sensitivity and specificity of USG in diagnosing GB carcinoma were 93.9 and 71.4% respectively. Similarly, the sensitivity and specificity of CT scan in detecting GB carcinoma were 97.1 and 83.3% respectively.

Our results showed that common clinical findings were nausea /vomiting in 52, upper abdominal pain 73, jaundice in 50, weight loss in 12, itching in 14 patients and upper abdominal mass in 8 patients. Jagdeesh et al,^[15] assessed the role of ultrasound as the primary diagnostic imaging modality in gallbladder diseases in 75 cases. Maximum incidence of gallbladder disease seen in the age group of 40-49 years and 69 (92%) of the cases were of gallstone. The total number of chronic cholecystitis was observed in 46 cases, among them 44 cases associated with gallstones and 2 cases were not associated with gallstones. 12 cases of gallstones were not associated with acute or chronic cholecystitis, there are 10 cases with acute cholecystitis. In 68 cases of gallstones, the clinical suspicion was proved correct in 32 cases, while radiology identified them correctly in 69 cases. Acute cholecystitis was correctly diagnosed clinically in 9 cases and by radiological means 10 in a total of 11 cases. Among the 44 cases of chronic cholecystitis, clinical diagnosis was correct in 7 cases and radiological diagnosis was correct in 44 cases. The radiological diagnosis was correct in 69 cases, among 68 cases of gall stones in 10 out of 11 cases with acute cholecystitis in 44 out of 44 cases

of chronic cholecystitis, in 5 out of 5 cases of gallbladder carcinoma in 1 out of 1 cases of gallbladder polyp.

Our results showed that common pathologies were polyps in 20, benign tumor in 14, acute cholecystitis in 13, chronic cholecystitis in 7 and gall stones in 25 patients. Hamdan et al,^[16] performed ultrasound scanning in 150 patients with GB disease. 76 patients (50.60%) were males and 74 patients (49.40%) were females. Incidence of gallstone were 88% (58.7%) patients and ratio of incidence was between female to males 13:9. Other pathologies of gallbladder were found to be cholecystitis 16.60%, polyp with sludge 16.60%, benign tumor 1.30%, normal 6.70%. They concluded that ultrasonography was a single imaging modality sufficient for evaluation of patient with suspected gallbladder pathologies.

USG findings were slight contraction in 56%, wall thickening was seen in 82%, acute acalculouscholecystitis in 14% and pericholecystic edema in 23%. Gupta et al,^[17] found that out of 120 patients, 70 were males and 50 were females. Age group 11-20 years consisted of males (4) and females (8). Age group 21-30 years consisted of males (11) and females (9). Age group 31-40 years consisted of males (17) and females (10). Age group 41-50 years consisted of males (13) and females (8). Age group 51-60 years consisted of males (15) and females (7). Patients > 60 years consisted of males (10) and females (8). Out of 120 patients, 35 were diagnosed with cholelithiasis. The prevalence was 29.1%. Out of 35 patients diagnosed with cholelithiasis, males were 20 and females were 15. Other abnormalities were wall thickening (27), slightly contraction (12), enlarge gall bladder with mass (10), acute acalculous cholecystitis (14), hepatic cyst (4) and pericholecystic edema (18).

In the ultrasonic image, gallstones appear as foci of dense echoes within the gallbladder lumen. These echoes do not depend on the stone's chemical structure or calcium content.^[18] Because of their high absorption of the ultrasonic beam, gallstones cast an acoustic shadow behind them. This characteristic is important in diagnosis. A less obvious stone impacted in the neck of the gallbladder also produces a shadow.^[19] When using 'real-time' scanners a further criterion for diagnosing gallstones is demonstrated movement of the echogenic focus within the gallbladder when the patient changes position. Ultrasound can detect gallstones to about 1 mm in size but unless these very small stones are aggregated, they usually do not cast an acoustic shadow.^[20]

CONCLUSION

Common USG findings were slight contraction, wall thickening, acute acalculouscholecystitis and pericholecystic edema. Common GB diseases were polyps, benign tumor, acute cholecystitis, chronic cholecystitis and gall stones.

REFERENCES

1. Bach AM, Loring LA, Hann LE, Illescas FF, Fong Y, Blumgart LH. Gallbladder cancer: can ultrasonography evaluate extent of disease? *J Ultrasound Med* 1998;17(5):303-9.
2. Courtney M. Townsend Jr. Sabiston Textbook of Surgery: The biological basis of modern surgical practice (textbook of surgery), 17th ed, WB Saunders 2004.
3. Kumaran V, Gulati S, Paul B, Pande K, Sahni P, Chattopadhyay K. The role of dual-phase helical CT in assessing resectability of carcinoma of the gallbladder. *Eur Radiol* 2002;12(8):1993-9.
4. Jane C. Figueiredo, Christopher Haiman, Jacqueline Porcel, James Buxbaum, Daniel Stram, Neal Tambe. E et al., Sex and ethnic/racial-specific risk factors for gallbladder disease. *BMC Gastroenterology*. 2017;(17):153:1-12.
5. Usha Dutta, Nikhil Bush, Dimple Kalsi, Priyanka Popli, Vinay K. Kapoor. Epidemiology of gallbladder cancer in India. *Chin Clin Oncol*. 2019;8(4):1-20.
6. Miquel JF, Covarrubias C, Villaroel L, Mingrone G, Greco AV, Puglielli L, Carvalho P, Marshall G, Del Pino G, Nervi F. Genetic epidemiology of cholesterol cholelithiasis among Chilean Hispanics, Amerindians, and Maoris. *Gastroenterol*. 1998;115(4):937-46.
7. Antonio Pinto, Alfonso Reginelli, Lucio Cagini, Francesco Coppelino, Antonio Amato Stabile Ianora, Renata Bracale et al. Accuracy of ultrasonography in the diagnosis of acute calculous cholecystitis: review of the literature. *Critical Ultrasound Journal*. 2013;5(1):S11:1-4.
8. Ferrucci JT: Body ultrasonography, Parts I and 2. *N Engl J Med* 1979; 300:538-542, 590-600.
9. Cooperberg PL, Burhenne HJ: Realtime ultrasonography, diagnostic technique of choice in calculous gallbladder disease. *N Engl J Med* 1980; 302:12 77- 1279.
10. Taylor KJW, Rosenfield AT, Spiro HM: Diagnostic accuracy of gray scale ultrasonography for the jaundiced patient: A report of 275 cases. *Arch Intern Med* 1979; 139:60-63.
11. Milner J, Hewitt D: The occurrence and treatment of gallbladder disease in Ontario. *J Chronic Dis* 1972; 25:75-83.
12. Price WH: Gallbladder dyspepsia. *Br Med J* 1963; 2:138-141.
13. Theodoro, D. Hepatobiliary. In: Ma, O.J., Mateer, J.R. and Blaivas, M., Eds., *Emergency Ultrasound*, McGraw- Hill, New Delhi. 2007; 177-186.
14. Laura M. Stinton and Eldon A. Shaffer. Epidemiology of Gallbladder Disease: Cholelithiasis and Cancer. *Gut and Liver*. 2012;6(2):172-187.
15. Ghafoor N, Abedin N, Mohiuddin AS. Role of ultrasound and computed tomography in the evaluation of gallbladder malignancy. *Anwer Khan Modern Medical College Journal*. 2017 Aug 23;8(2):105-11.
16. Jagadeesh K S, Ashwini M Patil. Ultrasonographic evaluation of gall bladder diseases. *MedPulse – International Journal of Radiology*. February 2020; 13(2): 60-65.
17. Hamdan et al. Evaluation of gallbladder diseases using ultrasonography. *Indian journal of applied research*. 2019; 1-4.
18. Gupta S, Jain AK. Ultrasonography as an imaging technique for the diagnosis of gall bladder disorders: A clinical study. *J Adv Med Dent Scie Res* 2017;5(1):79-82.
19. Bennett, G.L. and Blathazar, E.J. *Ultrasound and CT Evaluation of Emergent Gallbladder Pathology*. Radiologic Clinics of North America. 2003; 41: 1203-1216.
20. Rumack, C.M., Wilson, S.R. and Charboneau, J.W. *Diagnostic Ultrasound Volume 1*. 3rd Edition, Elsevier Mosby, Philadelphia. 2005.
21. Foster FS. Transducer material and probe construction of ultrasound. *Ultrasound Med Biol*. 2000; 26(1): 2-25.